

# Normals

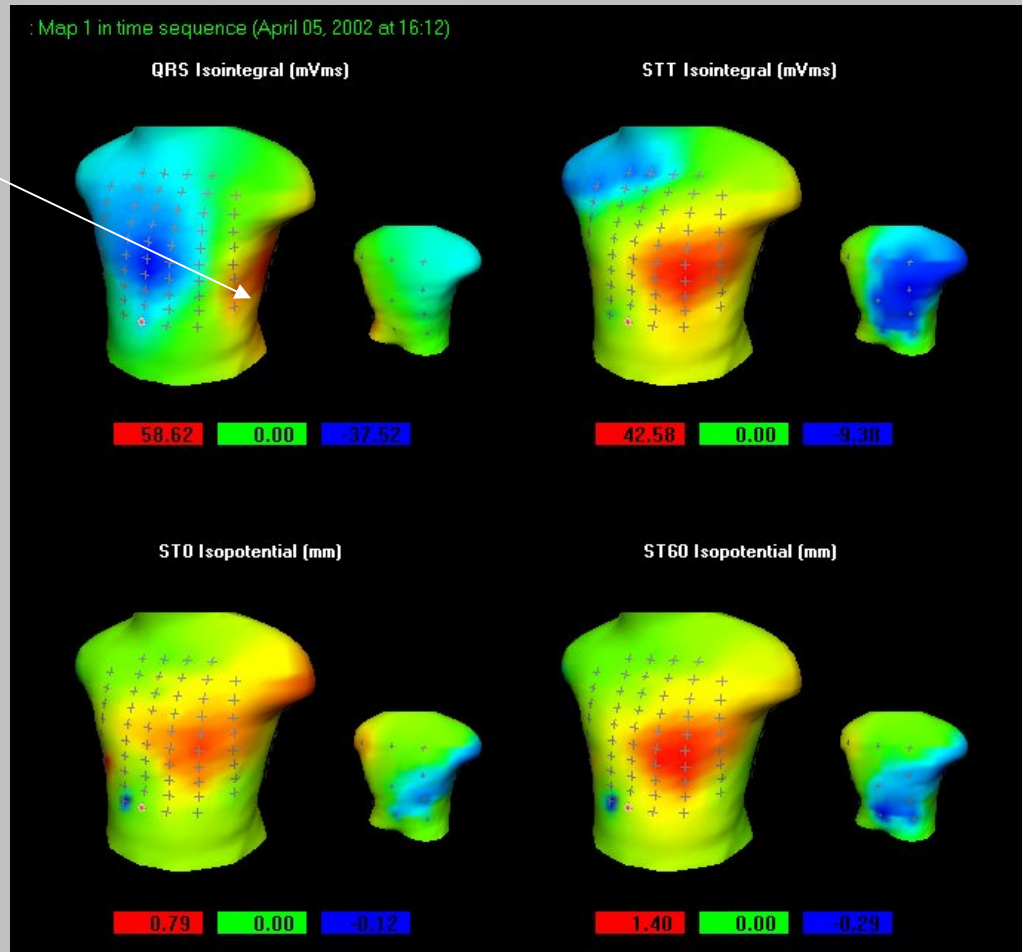
(See Demos-1-1 to 1-3)

# Normals

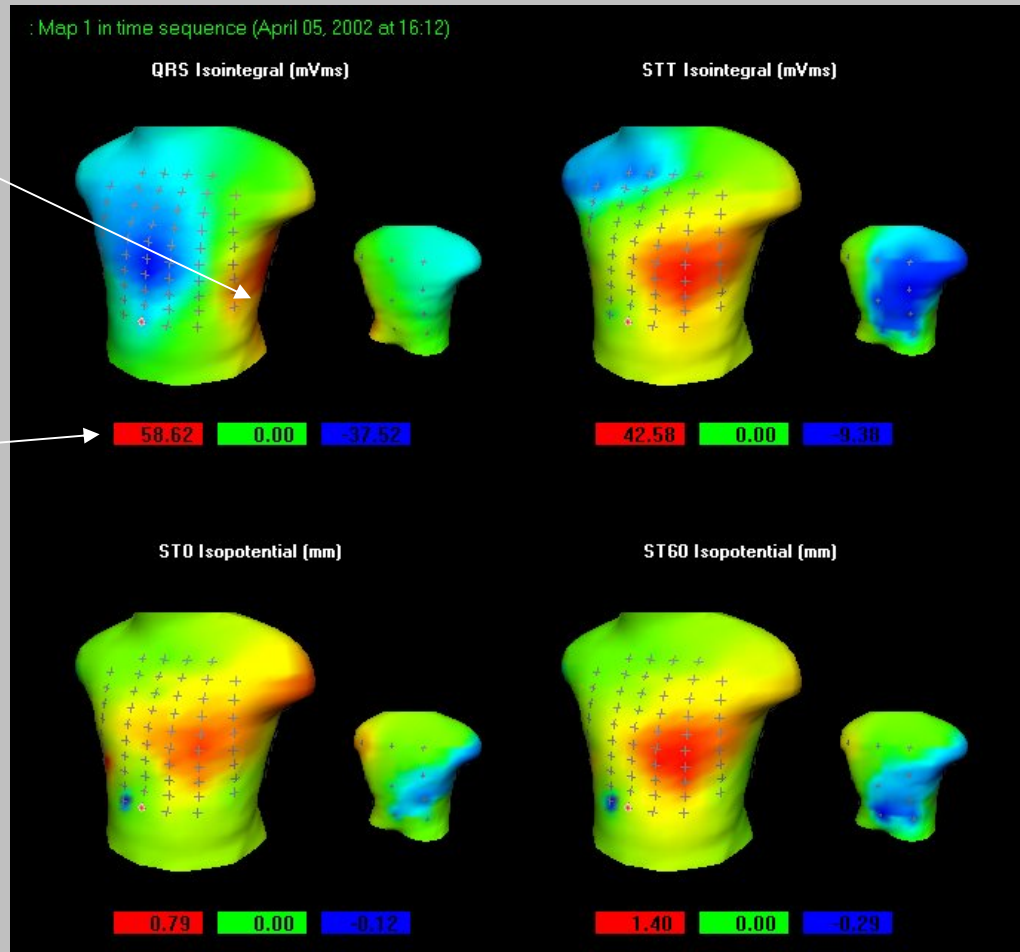
- Conduction within bounds
  - Axis deviation
  - QRS within +/- 50 (approx)
  - STT within +90/-40 (approx)
- ST within regional bounds
  - If small exceedance, check for Early Repolarisation or Pericarditis

# Demo Case 1-1

Axis OK



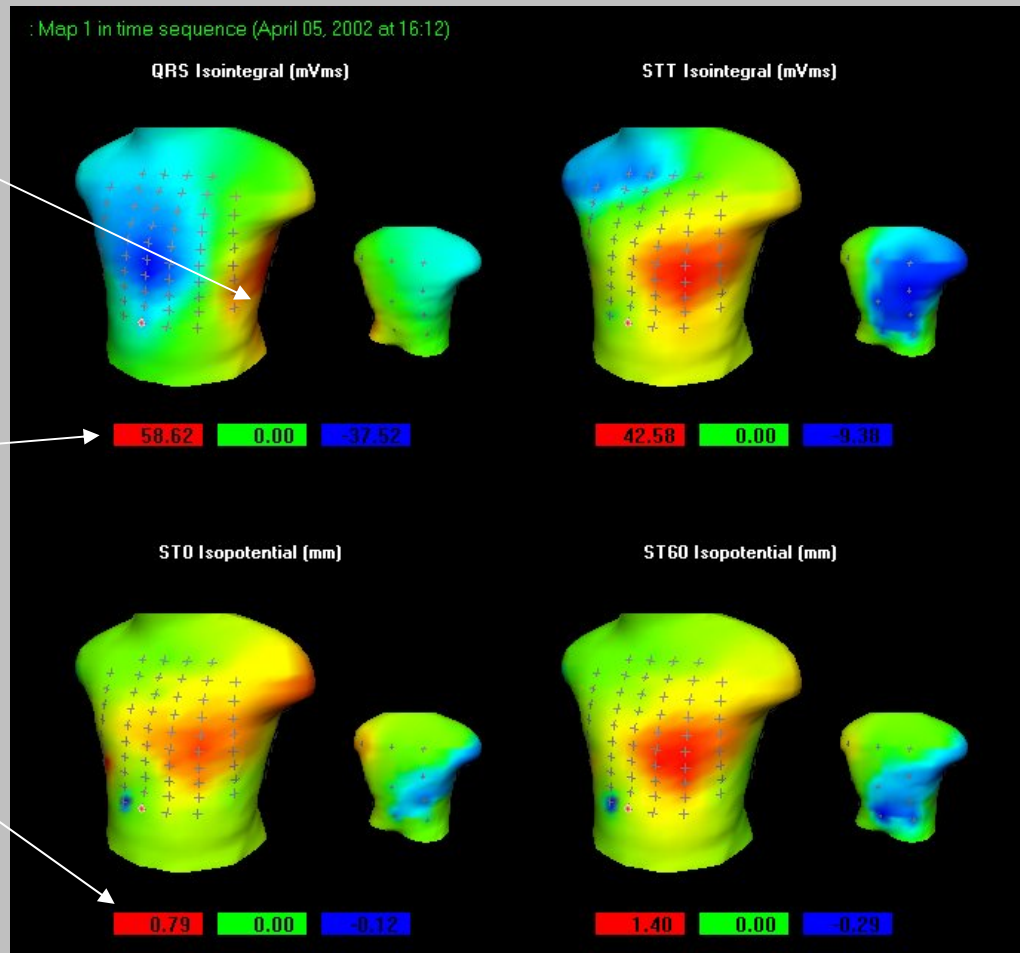
# Demo Case 1-1



Axis OK

QRS at +58 is just outside +50

# Demo Case 1-1

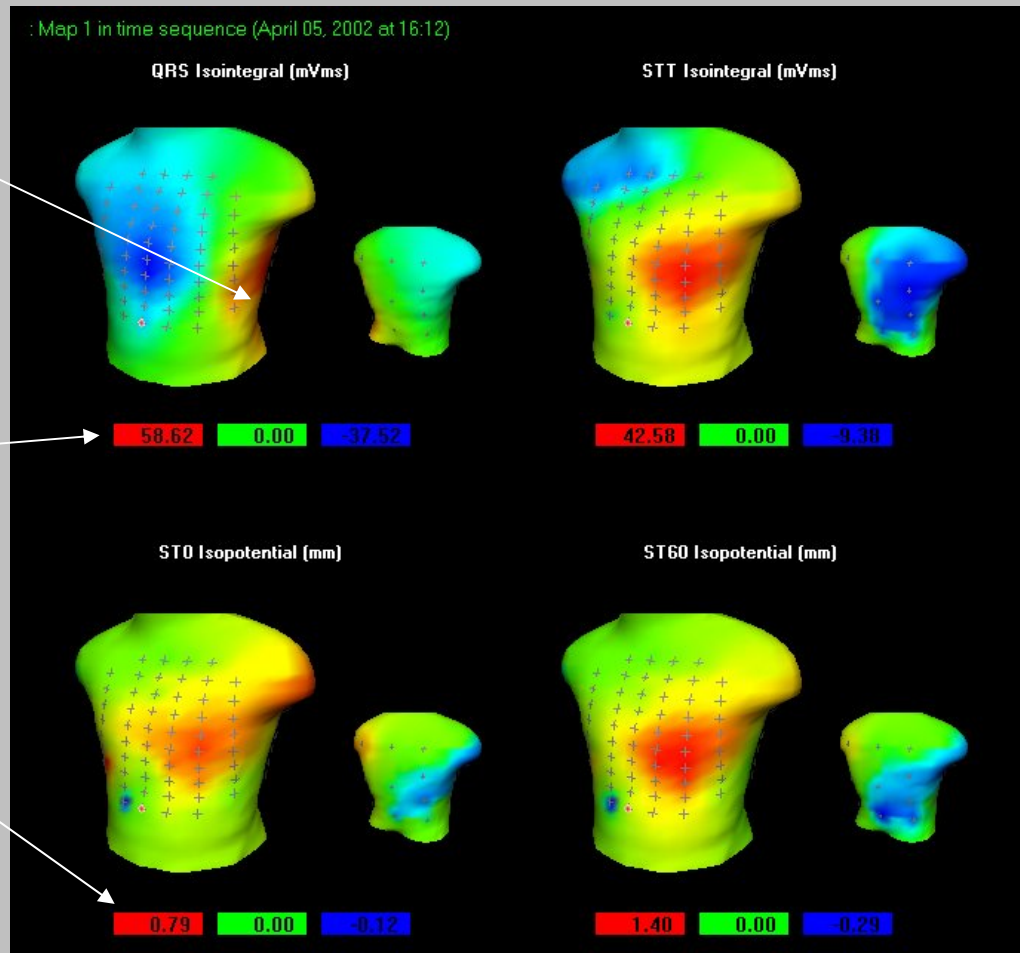


Axis OK

QRS at +58 is just outside +50

Max ST at 0.79 well within bounds for Anterior

# Demo Case 1-1



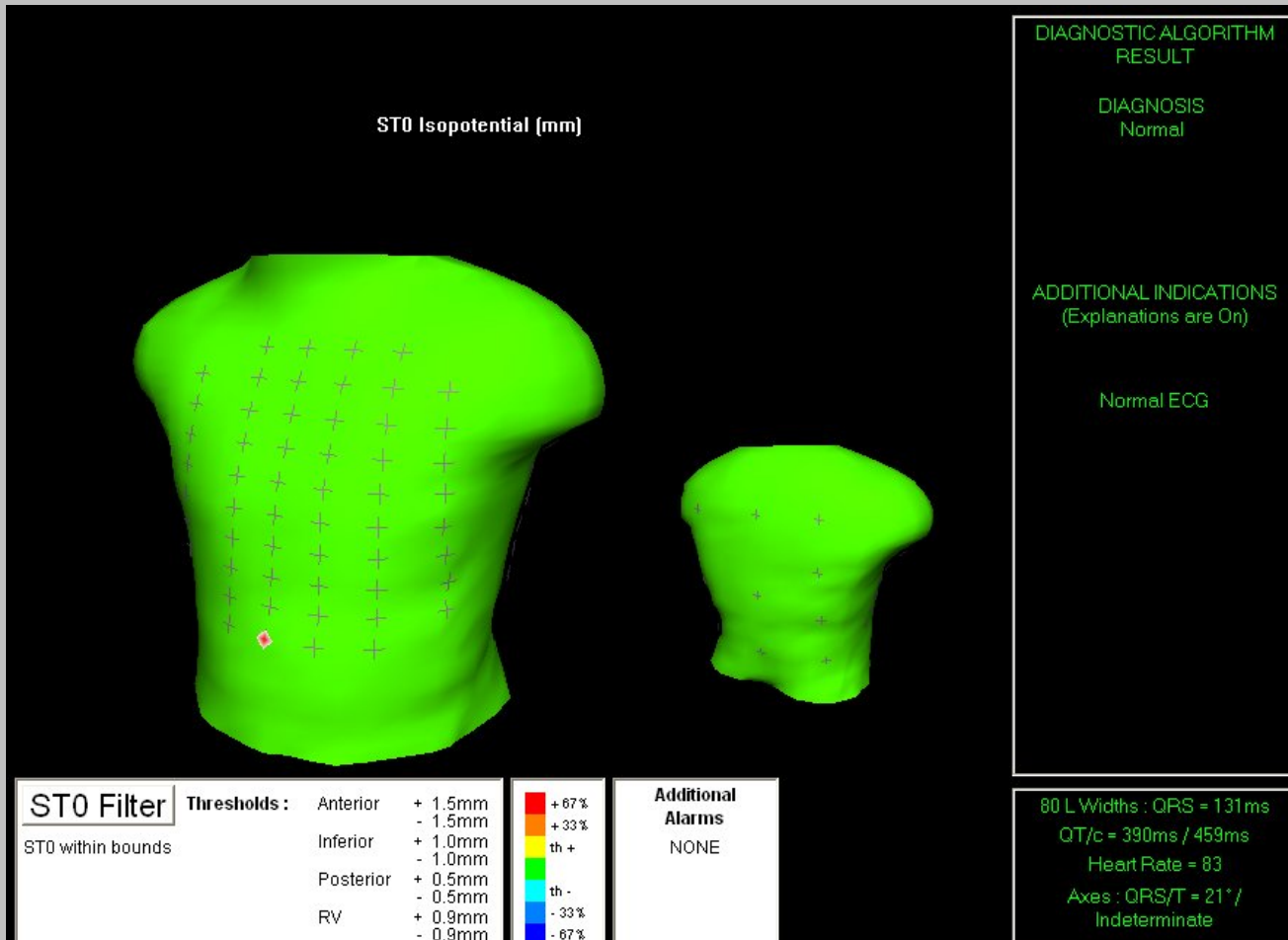
Axis OK

QRS at +58 is just outside +50

Max ST at 0.79 well within bounds for Anterior

Conclusion:  
NORMAL

# Confirmation - The “Jolly Green Giant”



# Look at Demo 1-2 & 1-3

- Demo 1-2
  - Axis OK
  - STT at +114 is a little out of +90 to -40 range, not by much
  - Max ST is 0.65 in Anterior – well in bounds
- Demo 1-3
  - Both QRS and STT well within bounds
  - ST0 is 1.3 in Anterior
- Both variants of Normal

# The End